

Upper and Lower Incisor Torque and Straight-Wire Appliance



Raffaele Spena

Private Practice in Orthodontics, Naples, Italy

Correspondence

Via dei Mille 13 • 80121 Naples • Italy
e-mail: rspen@tin.it

Article history

Received: 17/10/2013
Accepted: 10/01/2014

“ *How to increase flexibility and efficiency in reaching a better torque final position of the upper and lower anterior teeth when using straight-wire appliance* ”

Abstract

Biomechanical control of the torque of the upper and lower anterior teeth is critical in most treatments. Straight-wire appliances are designed to treat Class I and II malocclusions and overcorrections of the prescriptions are intended to help in Class I and Class II biomechanics. They are not designed for Class III malocclusions or Class III biomechanics and produce little control of severely proclined upper and lower incisors unless extremely valid anchorage is available and/or ample spaces are created in the arch. Rotation of 180° of an upper anterior straight-wire bracket is a common expedient frequently used by orthodontists to solve torquing needs. In this paper, rotation of the brackets of all four incisors during the initial stages of treatment to achieve the desired position and eventually overcorrect it, followed by their repositioning in the correct way to obtain final correct tip, torque and offset is described. Clinical and biomechanical situations are presented to show the advantages of such a simple stratagem.

Keywords

Straight-wire appliance, anterior torque, self-ligating brackets

INTRODUCTION

When, in 1972, L.F. Andrews published his article on the six keys to normal occlusion¹, the objectives of natural anatomical and functional dental treatment were described for the first time in the orthodontic literature. In the 1970s, the first straight-wire appliance (SWA) was presented: brackets with a specific tip, torque and offset for each tooth of the upper and lower arch became available. The SWA was presented as an appliance that should allow obtaining Andrews' six keys. However, cases treated with the original SWA showed some problems at the end of treatment: lack of incisor torque, molar mesial rotation, upper molar buccal flaring, rotation in the extraction sites and unlevelled curve of Spee. The appliance was unable to overcome the biomechanical problems during the treatment of common orthodontic problems. Andrews developed several (12 different ones) prescription brackets, called translation or extraction brackets², in an attempt to solve these orthodontic problems. However, it was impractical to have so many different brackets with slight differences in the prescriptions to treat everyday cases.

In 1976, Roth³ presented a SWA where selected overcorrected tip, torque and offset should have been effective in treating any malocclusion, accounting also for overcorrection, settling and solution for the common orthodontic biomechanical problems. Today, Roth's prescription brackets are still one of the most used SWAs.

A few years later, the MBT prescription⁴ and many others were on the market. The common idea of all the SWAs has been to allow an optimal dental position and occlusion to be achieved and to help with the common problems encountered in moving teeth from a pathological position to the desired

final position.

In the last 12 years, self-ligating brackets (SLBs) have acquired greater and greater popularity. The interactive SLBs allow great efficacy in expressing the torque (the most difficult information to obtain) built into the bracket. The last generation of thermal NiTi wires, used in combination with the interactive SLB, create a system that is highly effective in achieving tooth movement and final position in a very reliable way.

In this paper, we will refer to In-Ovation[®] SLBs with modified prescriptions (Fig. 1) but what will be described could be achieved with any pre-adjusted appliance.

LIMITS OF THE SWA

Every SWA, as any fixed and removable orthodontic system, has limitations in controlling the torque of the upper and lower anterior teeth. This problem may be partially overcome by the early expression of torque values during treatment with the use of square or rectangular thermal NiTi wires like the 0.020"x0.020" Bioforce[®] combined with active SLBs. Still, once working archwires such as 0.019"x0.025" stainless steel have been inserted, the anterior control may become critical when using intra- or intermaxillary forces.

The SWA appliances are all designed to treat Class I and II malocclusions and overcorrections are intended to help in Class I and Class II biomechanics. They are not designed for Class III malocclusions or Class III biomechanics. When treating Class III problems, one of the usual risks is ending up with flared upper incisors, lingually inclined lower incisors, shallow overjet and overbite. Often, it would be desirable to have buccal root torque on the upper incisors and lingual root torque on the lower incisors (Figs. 2 and 3).

At the same time, severely proclined

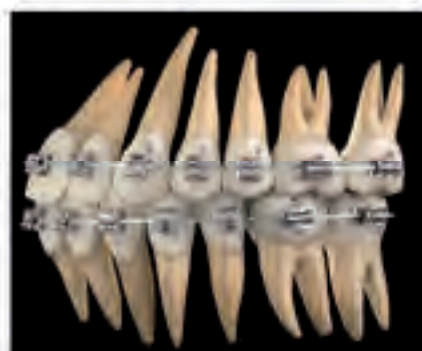

Figure 1: The In-Ovation[®] brackets and the new COO prescriptions.

© Registered trademark of GCH International, Bohemia, NY, www.gchintl.com

upper and lower incisors are biomechanically difficult to treat unless extremely valid anchorage control is available and/or ample spaces are created in the arch.

ROTATION OF THE STRAIGHT WIRE ANTERIOR BRACKETS

Rotation of 180° of the upper anterior SWBs is a common expedient frequently used by orthodontists to solve torquing needs. This different positioning allows the torque prescription to be changed while keeping all the other values unaltered. When an upper lateral incisor is palatally displaced, for example, by rotating the bracket and inserting a rectangular wire, it is possible to properly move buccally both the crown and the root and, possibly, to overcorrect the final root positioning, thus increasing stability. Even the most sophisticated machine (appliance) needs a thinking pilot (clinician) and has to have the flexibility to treat different orthodontic problems. The idea is that all four anterior brackets may be used in a conventional way or rotated 180° according to the torquing needs. This "unconventional positioning" can be done temporarily during the initial stages of treatment to achieve the desired position and eventually overcorrect it. In the final stage of detailing, brackets may be



Figures 2, 3: Undesired final result after Class III treatment. Class III biomechanics may need buccal root torque on upper incisors and lingual root torque on lower incisor.



Figure 4: Adult patient with Class III malocclusion and dental and skeletal asymmetry.

repositioned in the traditional way to obtain the correct torque, tip and offset, as present in the SWA.

PROPOSAL FOR CLASS III MECHANICS

Class III malocclusions may present in a wide range of severity. Some may need surgery and some may be successfully treated with orthopaedic-orthodontic treatment. Class III mechanics requires exceptional control of the rotation of the occlusal plane and of the upper and lower anterior torque. In both the lower and the upper arch, all teeth must be included in the multibracket appliance and heavy stainless steel wires must be used in the working stage.

The initial position of the incisors and the width of the symphysis and the premaxilla on cone beam computed tomography (CBCT) scans should be carefully evaluated. This may influence the appropriate torquing needs and the consequent

positioning of the anterior brackets. If the upper incisors are flared and the premaxilla is anteroposteriorly wide enough, it is recommended to position all four upper anterior brackets rotated 180° to have a buccal root torque. If the lower incisors are upright or lingually inclined, all four anterior brackets need to be rotated to produce a lingual root torque that will counteract their tendency to incline even more lingually under the Class III mechanics.

As said before, the brackets' rotated position may be kept as long as the Class III mechanics is needed. When the final stage of detailing is reached, the anterior brackets may be rebonded (rebonding is a common practice when using fixed appliances and, even more so, SWA) in the conventional way to obtain the desired final tooth position. In a study conducted on the effective expression of torque when using active SLB, Gicket al. have shown how

torque depends on the wire and slot dimension⁶. In a 0.022" slot, torque is expressed by 77% when using a 0.017"x0.025" wire, by 86% when using a 0.018"x0.025" wire and by 100% when using 0.019"x0.025" or greater wires. These differences may be considered to help decide how much torque expression is desired and to choose the appropriate wire to insert in the anterior bracket slots during Class III mechanics.

In *Figures 4-10*, a Class III malocclusion in an adult patient is shown. The patient's family refused the proposed combined orthodontic-surgical treatment. It was decided to treat the malocclusion only with orthodontics. At the beginning of treatment, both the upper and the lower incisors were proclined. It was decided to rotate only the upper incisors to produce a buccal root torque. The lower anterior brackets were bonded in a conventional way to produce a lingual root torque to achieve a more upright final position.

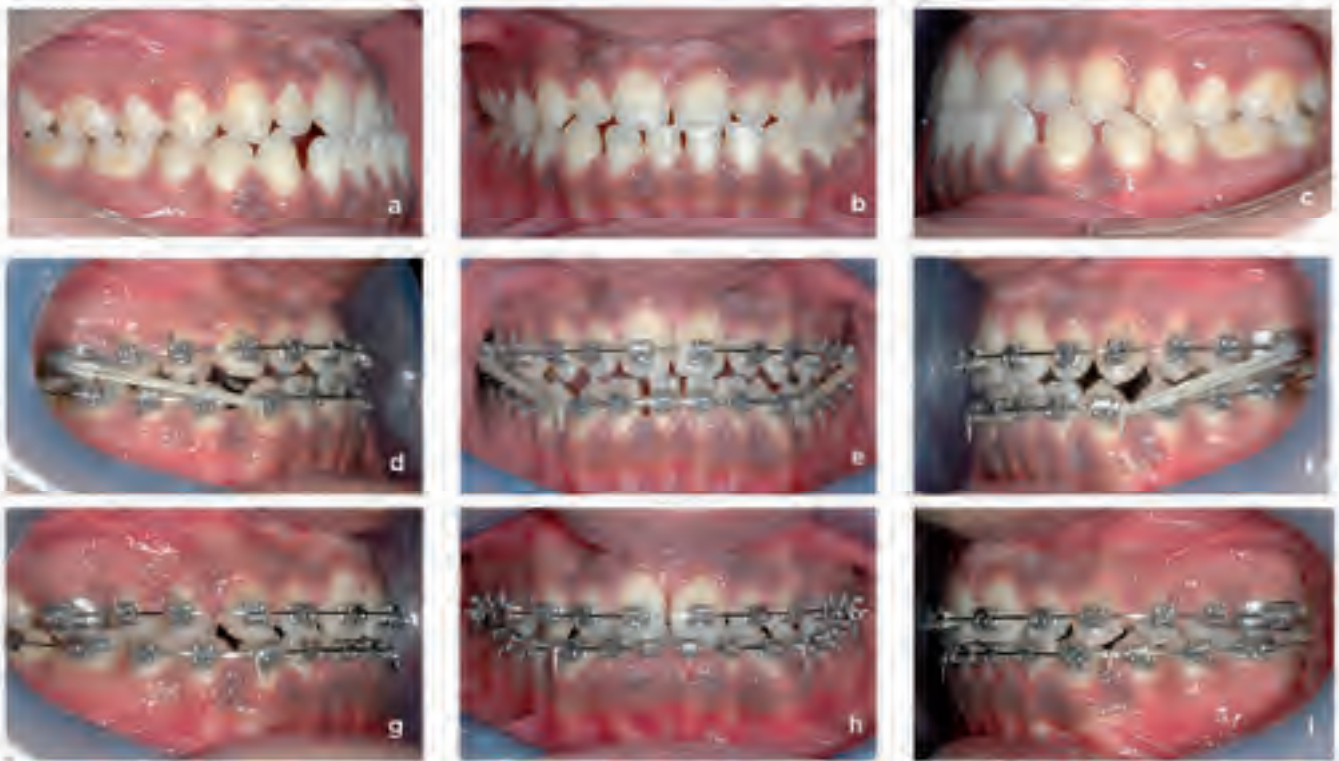

Figure 5 (a-i): Intraoral pictures of the initial malocclusion and the stages of the orthodontic treatment. The brackets on the anterior teeth have been bonded rotated 180°. Class III mechanics have been conducted on upper and lower 0.019"×0.025" stainless steel wires.



Figure 6: Patient at the end of treatment. The predominance of the chin as well as the asymmetry have been reduced.

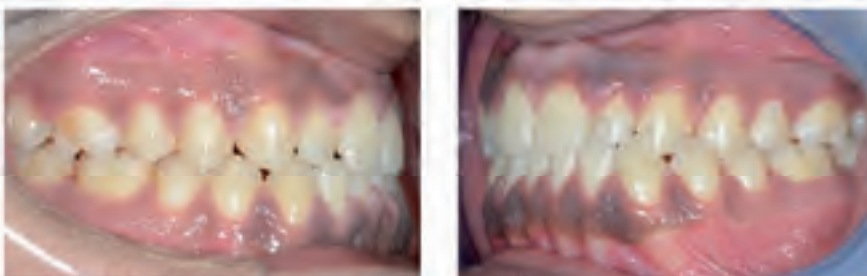

Figure 7: Intraoral pictures at the end of treatment. The Class III relationships have been solved and acceptable overjet and overbite have been achieved.

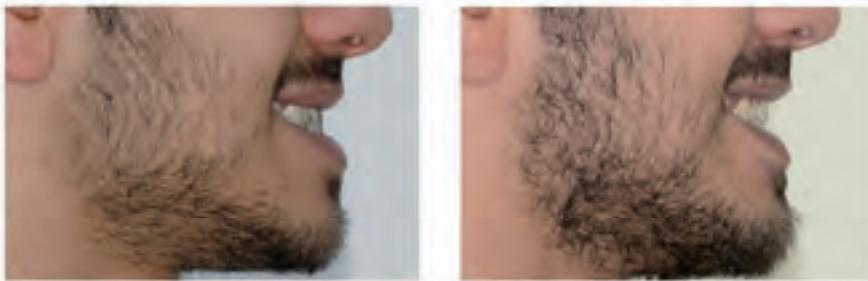

Figure 8: Close-ups of the initial and final smile of the patient. Note the improved appearance of the upper and lower incisors

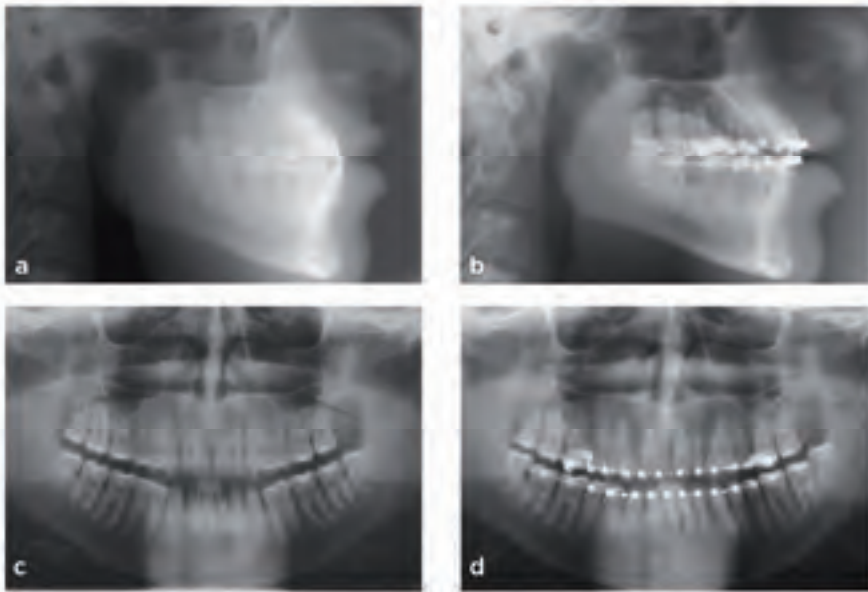


Figure 9 (a-d): Close-ups of the initial and final(before debonding) lateral cephalograms and panorex

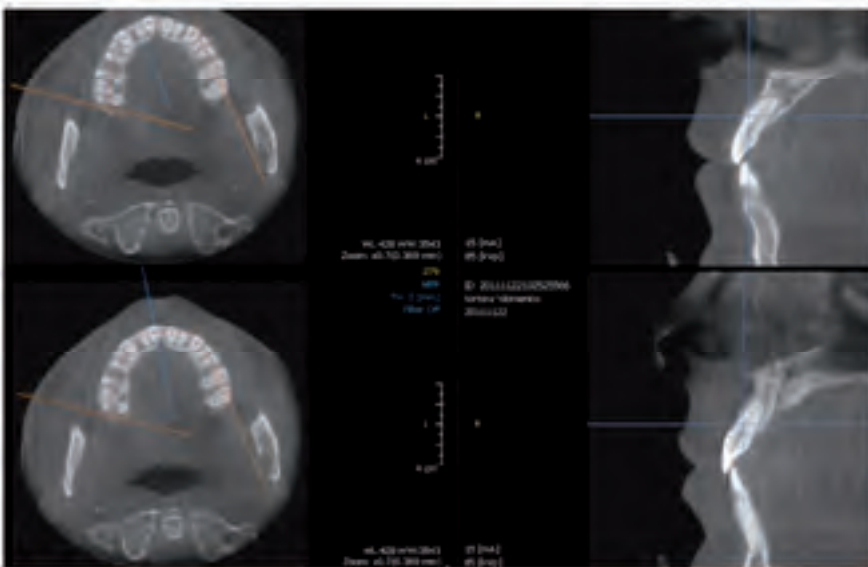


Figure 10: CBCT scans of the right upper central and lateral incisors at the end of treatment. Careful evaluation of the width of the premaxilla and the position of the roots allows to proper final positioning



Figure 11: Adolescent patient with Class III malocclusion and dental bimaxillary protrusion.

Figures 11–16 show the treatment and the end result in a growing patient with a bimaxillary dental protrusion and a Class III skeletal relationship.

PROPOSAL FOR PROCLINED INCISORS

Malocclusions with bimaxillary dental protrusion may need different solutions according to the aesthetic, functional and periodontal objectives. Extractions of premolars and maximum posterior anchorage may be needed for the most severe biprotrusions. In mild cases, minor

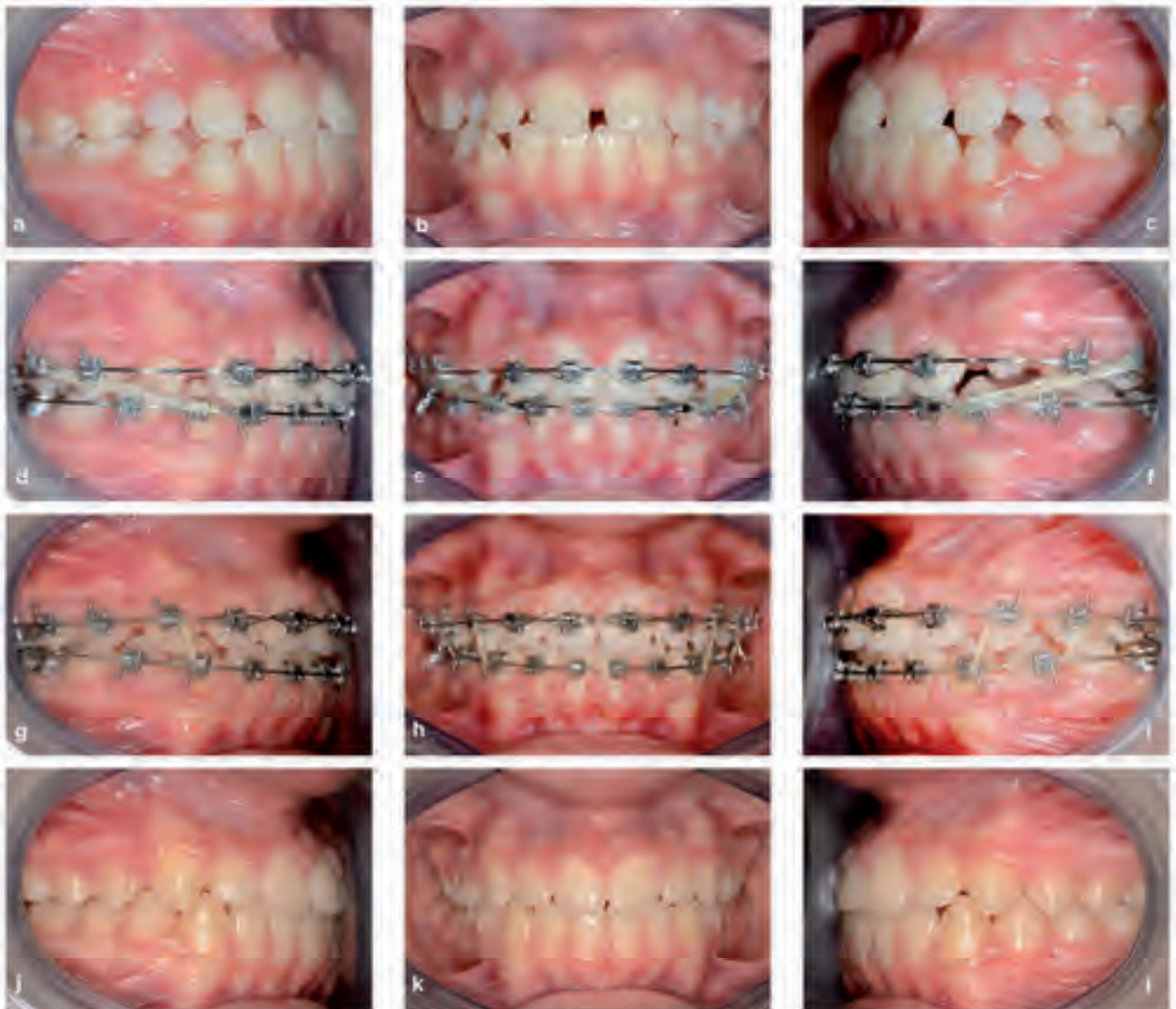

Figure 12 (a–l): Intraoral pictures of the initial malocclusion, the stages of the orthodontic treatment and the final result. The brackets on the anterior teeth have been bonded rotated 180°. Class III mechanics have been conducted on upper and lower 0.019"×0.025" stainless steel wires. Final settling with upper and lower 0.019"×0.

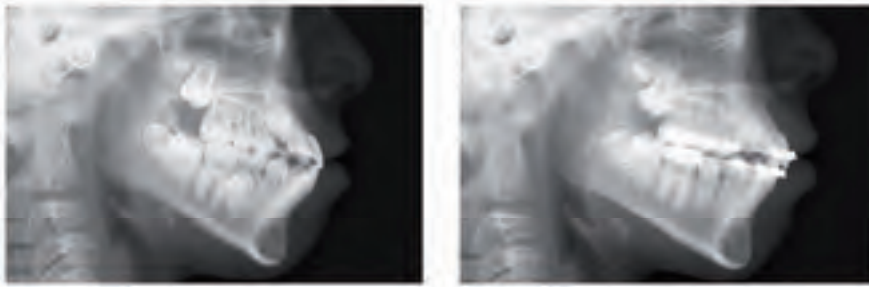


Figure 13: Close-ups of the initial and final (a few months before debonding) lateral cephalograms.



Figure 14: Patient at the end of treatment. The procumbency of the anterior teeth has been reduced without flattening the patient's beautiful profile.

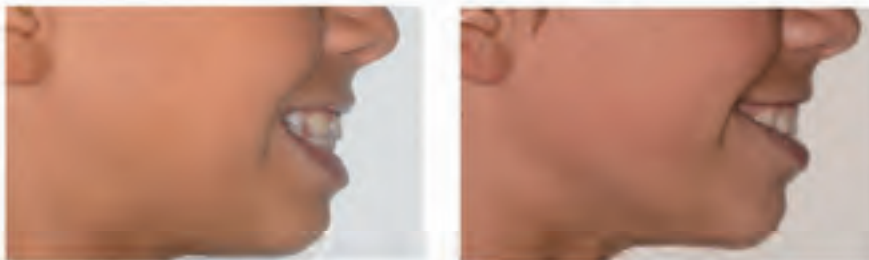

Figure 15: Close-ups of the initial and final smile of the patient. Note the improved appearance of the upper and lower incisors.

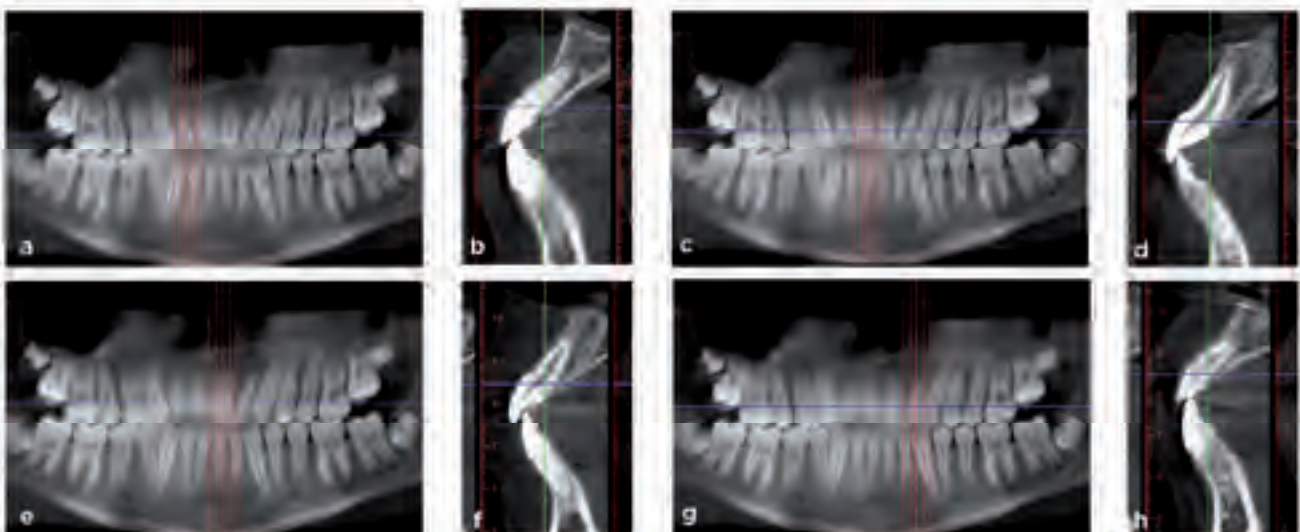


Figure 16 (a-b): Final CBCT scans of the anterior teeth to evaluate the relationship between the roots of the incisors and the premaxilla and the symphysis.

space gaining and proper torque of the upper and lower incisors may be indicated (Fig. 17).

SWAs do not help in these situations. The new Complete Clinical Orthodontics (CCO)[®] prescriptions have -6° in the lower anterior teeth, which are more effective in obtaining the desired final upright position. In the upper arch, during the final part of the levelling phase, when square or rectangular thermal NiTi wires are used, and during the working stage of biomechanics with rectangular stainless steel wires, the anterior brackets may be rotated 180° to produce buccal root torque. Again, the width of the premaxilla on CBCT scans and of the initial

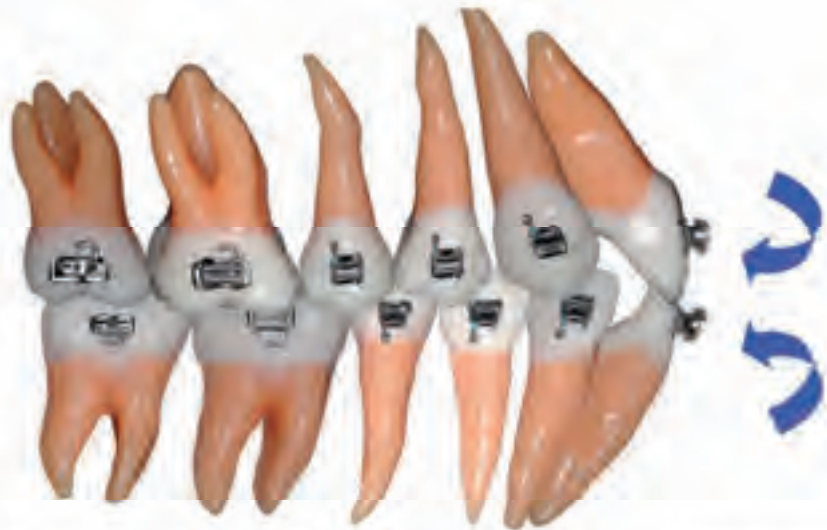

Figure 17: Mild upper and lower dental anterior protrusion may be solved by minor space gaining in the arches and buccal root torque on both the upper and lower incisors.

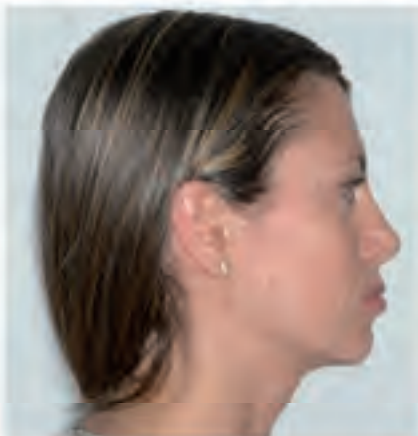

Figure 18: Patient with a dental bimaxillary protrusion at the beginning of treatment. The patient's objective was to reduce procumbency of the anterior teeth. Having already extracted all four third molars, the patient refused to have any further teeth extracted.

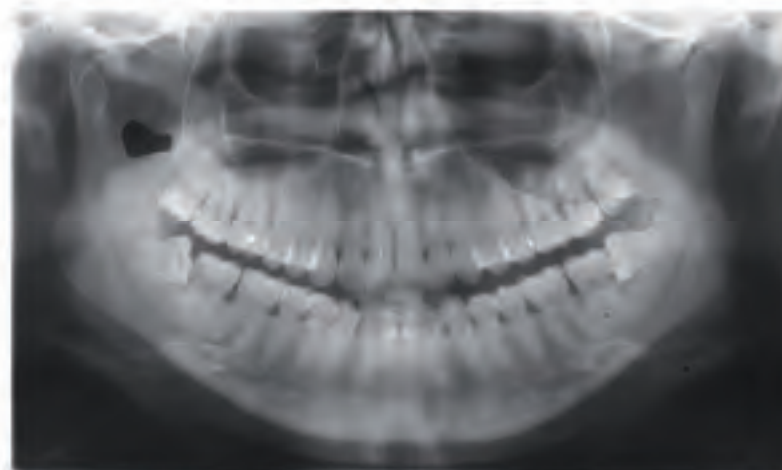
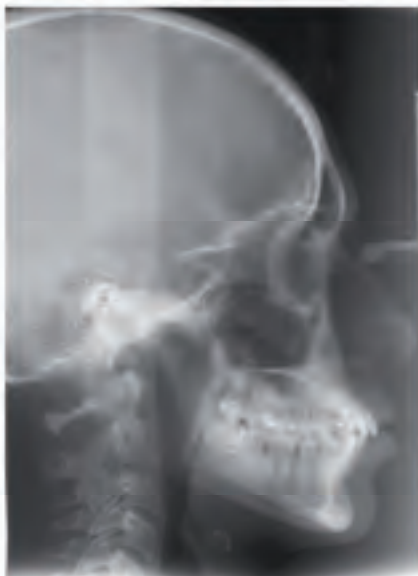


Figure 19: Initial lateral cephalogram and panorex. Note the procumbency of the anterior teeth and the four third molars that have been extracted before the beginning of the orthodontic treatment.

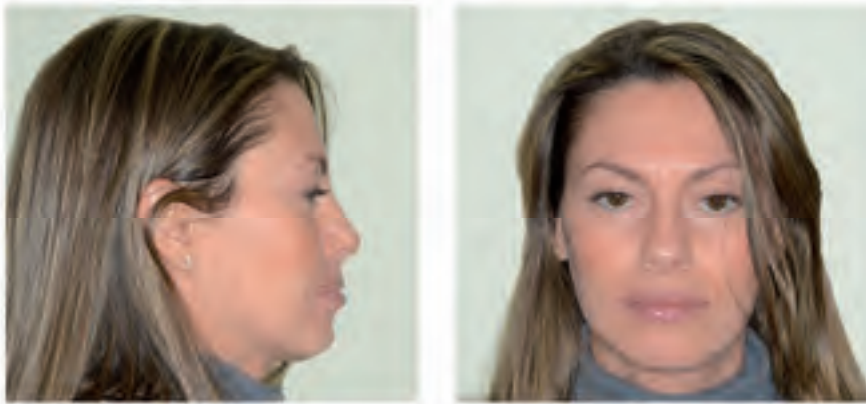

Figure 21: Patient at the end of treatment. The procumbency of the anterior teeth has been reduced without flattening the patient's beautiful profile.

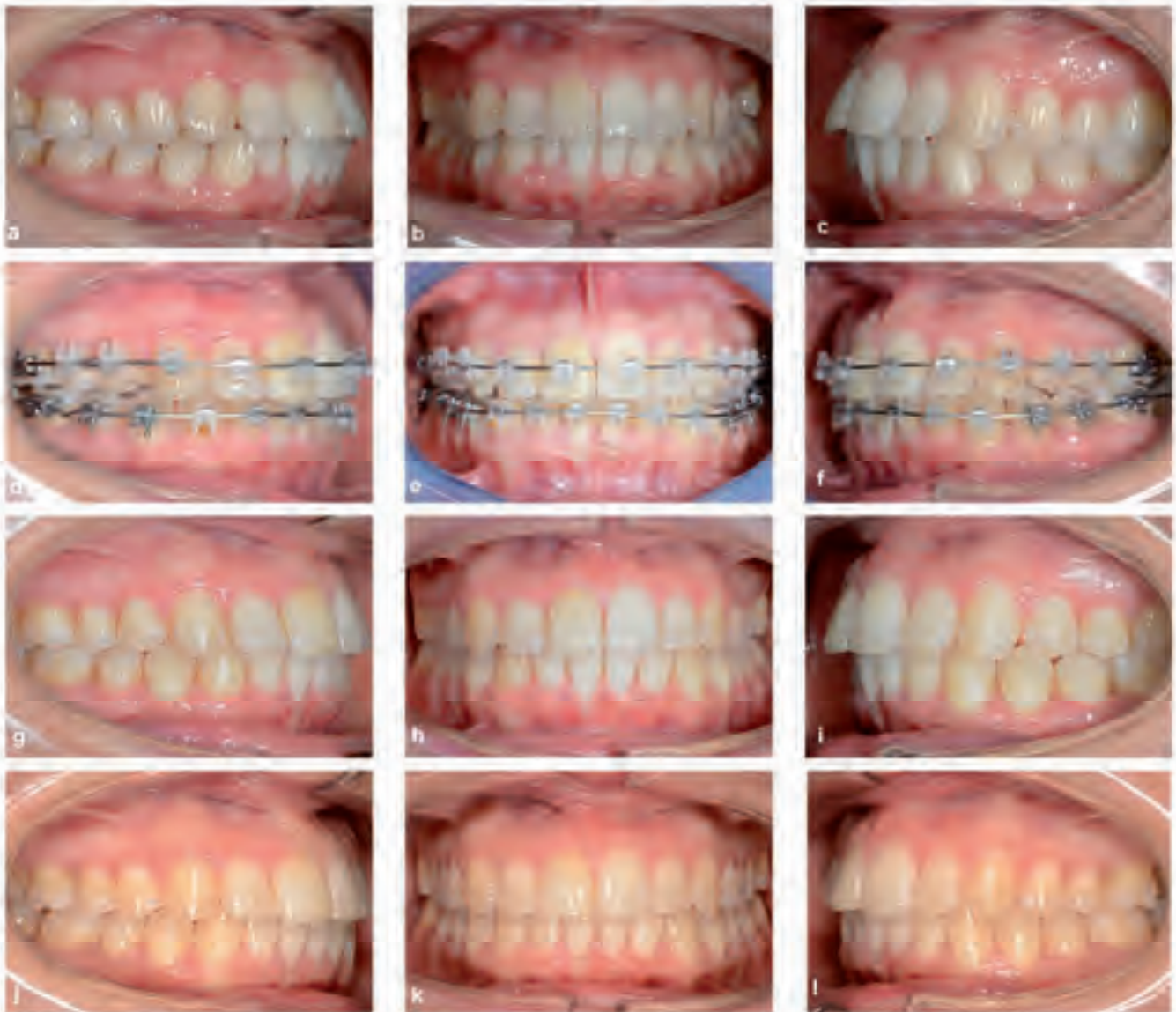

Figure 20 (a-i): Intraoral pictures of the initial malocclusion, the stages of the orthodontic treatment, the end of treatment and 2 years post-treatment. The anterior brackets on the anterior teeth have been bonded 180°. Space in the arches has been created with stripping. Treatment time was 10 months.

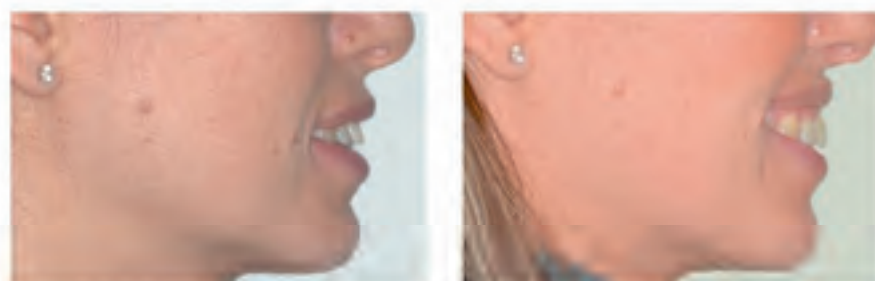

Figure 22: Close-ups of the initial and final smile of the patient. Note the improved appearance of the upper and lower incisors.

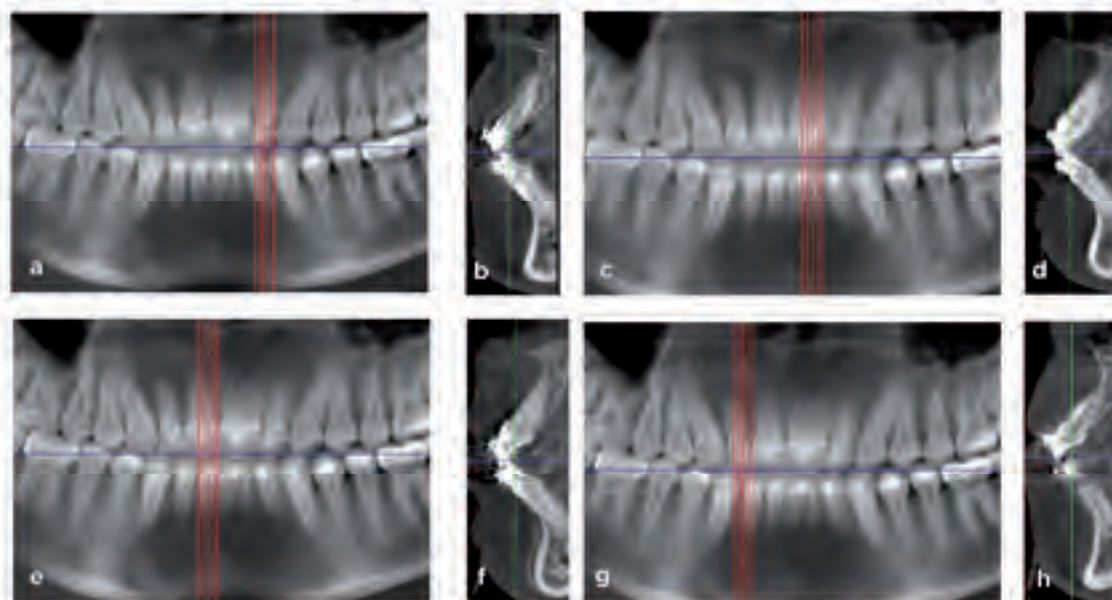


Figure 23 (a–b): Final (before debonding) CBCT scans of the anterior teeth to evaluate the relationship between the roots of the incisors and the premaxilla and the symphysis.



Figure 24: Initial facial photos of the patient. Note the slight mandibular retrusion.

and the forecasted final position of the roots of the anterior teeth must be accurately evaluated. In the final stage of treatment (of detailing), the brackets may be repositioned in the normal way. This procedure may be indicated also for Class I malocclusions with upper incisor protrusion.

In Figures 18–23 and Figures 24–28, two clinical cases treated as described are shown.

CONCLUSIONS

SWAs may present limits in controlling the torque of the anterior teeth in certain clinical and biomechanical situations. Changing move incisor roots, the anterior torque prescriptions to more effective and flexible values and rotating active self-ligating brackets as needed may improve biomechanical management and results in Class III malocclusions

and in upper and/or lower incisor protrusion. CBCT scans should be routinely taken before and after treatment to accurately evaluate the anatomical boundaries in which to move incisor roots.

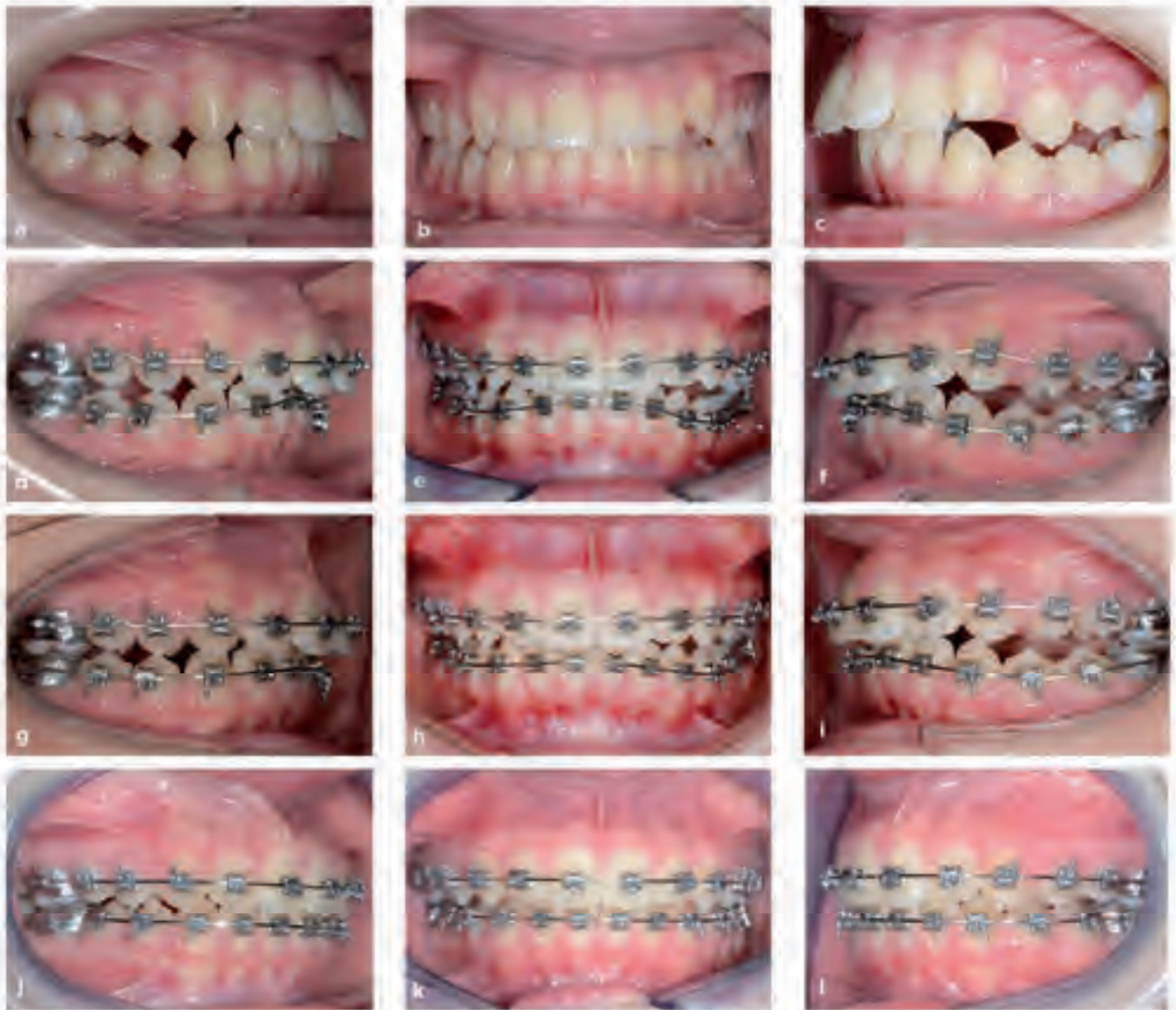

Figure 25 (a-l): Intraoral pictures of the initial malocclusion and the stages of the orthodontic treatment. The In-Ovation brackets on the upper anterior teeth have been bonded rotated 180°. No intermaxillary elastics have been used.

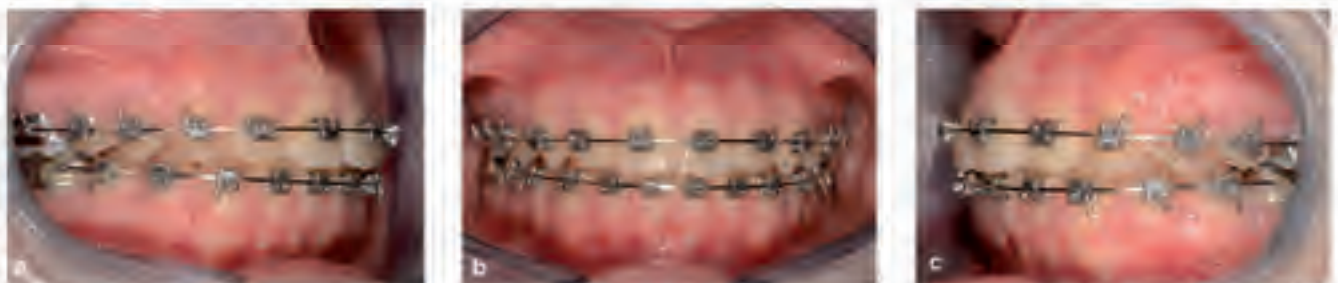


Figure 26 (a-c): At this stage of the treatment, brackets have been rebonded in the conventional position.

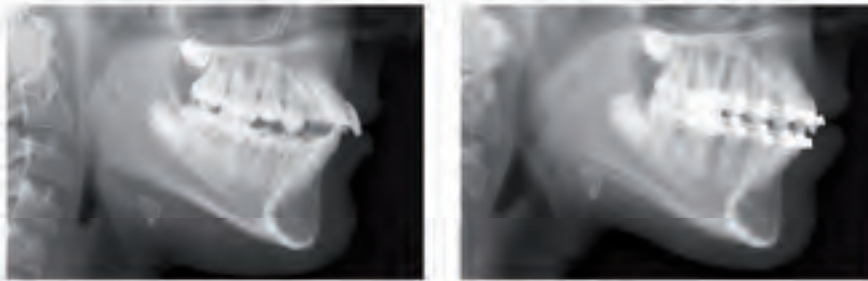


Figure 27: Close-ups of the initial and progress lateral cephalograms. Note the improved torque of the upper and lower incisors.

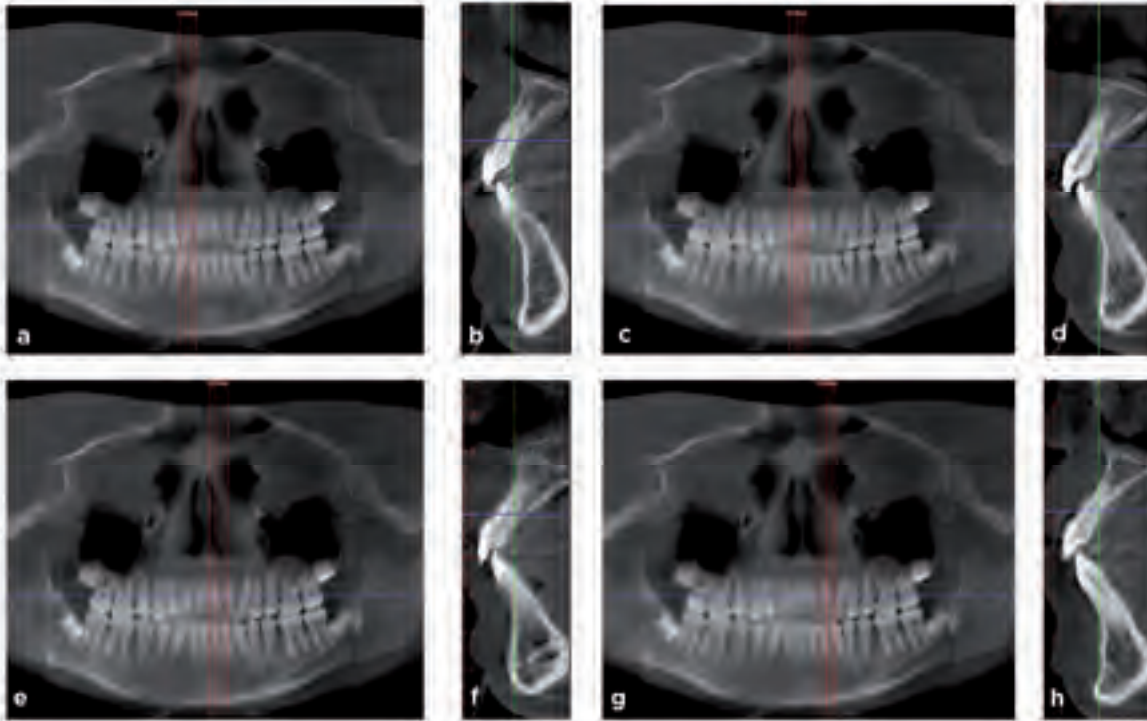


Figure 28 (a-h): Final CBCT scans of the anterior teeth to evaluate the relationship between the roots of the incisors and the premaxilla and the symphysis.

REFERENCE LIST

<p>1. Andrews LF. The six keys to normal occlusion. <i>Am J Orthod</i> 1972;62:296-308.</p> <p>2. Andrews LF. The straight-wire appliance: the extraction series. <i>J Clin Orthod</i> 1976;10: 99-114, 282-303, 360-379, 425-433, 507-529.</p> <p>3. Roth HR. Five year clinical evaluation</p>	<p>of the Andrews straight-wire appliance. <i>J Clin Orthod</i> 1976;10:836-850.</p> <p>4. McLaughlin RP, Bennett JC. The transition from standard edgewise to preadjusted appliance systems. <i>J Clin Orthod</i> 1989;23:142-153.</p> <p>5. Gick MR, Nóbrega C, Benetti</p>	<p>JJ, Jakob SR, Zucchi TU, Arsati F. Comparative study of torque movement induced by self-ligation and conventional systems. <i>Orthod Sci Pract</i> 2012;5:37-46.</p> <p>6. Secchi AG. Complete Clinical Orthodontics: Syllabus and Course Manual. DoctorOs AriesDue, 2012.</p>
--	---	--